



Contents lists available at ScienceDirect

Journal of Clinical Tuberculosis and Other Mycobacterial Diseases

journal homepage: www.elsevier.com/locate/jctube

Tuberculous appendicitis: A review of reported cases over the past 10 years

Grant Hubbard^{*}, Walter Chlysta

Western Reserve Hospital, Department of Surgery, 1900 23rd St, Cuyahoga Falls, OH 44223, USA

ARTICLE INFO

Keywords:

Tuberculous appendicitis
Appendix
Extrapulmonary tuberculosis
Gastrointestinal tuberculosis
Surgery
Public health

ABSTRACT

Background: Tuberculous appendicitis is a rare extrapulmonary manifestation of tuberculosis without clear summarization or consensus on its management.

Data sources: Case reports were gathered from several online literature databases by searching terms “tuberculosis”, “tuberculous”, and “appendicitis”.

Report eligibility criteria: Cases of appendicitis due to *M. tuberculosis* identified on operative histology. Exclusion criteria: appendicitis caused by a mycobacterium other than *M. tuberculosis*, and appendiceal tuberculosis identified incidentally during procedures for other reasons.

Results: Thirty four patients were identified. Twenty five patients presented with acute right lower quadrant abdominal pain. Eleven patients described chronic symptoms of tuberculosis (cough, night sweats, or weakness/fatigue). Four patients had a known diagnosis of TB. Seven of 24 cases reported peri-operative chest imaging which demonstrated pulmonary lesions. AFB were present in tissue or fluid samples of 6 patients, and negative in 15 patients. All patients underwent pharmacotherapy on a WHO-recommended anti-tuberculous treatment (ATT) with RIPE or an alternative. The average duration of treatment was 7.2 ± 1.7 months.

Limitations: Data was gathered from case reports without complete uniformity in diagnostic work-up. The potential for larger scale study is limited due to disease rarity.

Conclusions: Tuberculous appendicitis cannot be diagnosed prior to histologic evaluation. Several data points may suggest the disease on a clinician’s differential diagnosis if they present with a combination of the following: born in a country with endemic tuberculosis; chronic cough, weakness/fatigue, or nausea prior to onset of abdominal pain; pulmonary lesions on chest X-ray; white studding of the mesentery or peritoneum in a young patient; positive AFB stain of abdominal fluid or peritoneal tissue.

1. Background

An overall reduction in the prevalence of Tuberculosis (TB) has been noted over the last decade in both the developed and developing world, due in large part to systematic efforts toward its treatment and eradication [1]. Tuberculous appendicitis is a rare clinical entity, with a reported incidence of 1.5–3.0% among patients with tuberculosis [2]. Tuberculous appendicitis was first described by Corbin in 1873 and has seen little change in its incidence since that time. The challenge presented by this disease lies in its prompt identification and diagnosis. Patients present identically to patients with non-tuberculous cases of appendicitis, with the final diagnosis of tuberculous appendicitis only made upon report of histologic findings [3]. Oftentimes, these patients will present without a previous history of pulmonary tuberculosis, or even without suggestive symptoms. According to prior literature, only 14% of gastrointestinal TB will demonstrate suggestive findings on chest

X-ray [4].

The time spent between presentation, operation, and diagnosis yields an amount of time during which a patient with appendiceal tuberculosis will remain on a nursing floor, in a non-isolated room, exposed to other patients and healthcare workers. This is a concerning statistic when considering prior reviews and prior reports from the World Health Organization (WHO) which state that rates of TB infection in healthcare workers are twice that of the general population [5,6]. The risk is further exacerbated in countries with endemic TB [7]. This window of exposure presents a risk of transmission, and raises the question “how can we improve?”

In the US, extrapulmonary disease is seen in 20–30% of patients with TB [8]. Of the extrapulmonary manifestations, it is reported that bone involvement by TB is most common (30%), followed by the urinary tract (24%), and perihilar lymph nodes (13%) [9]. Involvement of the gastrointestinal tract varies widely in the literature, with a reported

^{*} Corresponding author.

E-mail address: g Hubbard@westernreservehospital.org (G. Hubbard).

<https://doi.org/10.1016/j.jctube.2021.100228>

Available online 18 March 2021

2405-5794/© 2021 The Authors.

Published by Elsevier Ltd.

This is an open access article under the CC BY-NC-ND license

(<http://creativecommons.org/licenses/by-nc-nd/4.0/>).

prevalence between 3 and 10% [10]. Tuberculous appendicitis occurs even less frequently, constituting 10% of gastrointestinal infections, or 0.03–0.1% of extrapulmonary infection [11,12]. Ileocecal infection comprises 75% of all intestinal TB infections [10]. It should be noted that two of the most recently published series of patients do not report a single case involving the appendix [13,14].

The characteristic histologic findings to make the diagnosis of tuberculous appendicitis include caseating granulomas, epithelioid histiocytes, and Langhans giant cells [12]. Fig. 1 below includes examples of these findings within appendiceal tissue for reference.

Following diagnosis, patients with tuberculous appendicitis have been treated with standard antituberculosis therapy (ATT) [15] and appendectomy. Other forms of gastrointestinal tuberculosis often do not require surgery, with the majority of cases of tuberculosis affecting the gastrointestinal tract successfully treated with ATT [16]. These forms of infection are frequently discovered as part of other work-up for pulmonary tuberculosis, chronic diarrhea, chronic abdominal pain, etc.

2. Objectives

This study aimed to review case report findings over the past 10 years. The primary objective was to evaluate the disease burden, symptomatology, diagnostic methodology, and diagnostic difficulties associated with tuberculous appendicitis.

3. Methods

PubMed and Google Scholar databases were queried with the terms “tuberculosis”, “tuberculous”, and “appendicitis”. The databases BIOSIS, DeepDyve, Science Citation Index Expanded (SCI-EXPANDED), Social Sciences Citation Index (SSCI), and Conference Proceedings Citation Index- Science (CPCI-S) were also queried with the same MeSH terms and searches did not yield any additional reports. Case reports from the years 2010 through 2021 reviewed for patient presentation, methods of diagnosis, and treatments. This timeframe was chosen due to the ease of access in literature databases. Exclusion criteria were: cases of

appendicitis caused by a mycobacterium other than *M. tuberculosis*, and appendiceal tuberculosis identified incidentally during procedures for other reasons (e.g. right hemicolectomy for colon cancer). The cases were then categorized and grouped based on presenting demographics, symptoms, diagnostic findings, treatment modalities, and surgical findings.

4. Results

Thirty four cases of Tuberculous Appendicitis were reported in 27 papers [2,9,10,16,17,25–46]. Baseline characteristics are reported in Table 1. Twenty patients were male and 16 were female. Presenting symptoms are reported in Table 2. The average age of patients was 25.5 ± 8.8 years. Twenty eight patients (82%) presented with acute onset or worsening of right lower quadrant abdominal pain. Twelve patients (35%) of patients complained of vague or generalized chronic abdominal pain (defined as greater than 7 days). Eleven patients (33.3%) described chronic symptoms of cough, night sweats, or weakness/fatigue; including 1 patient with known active pulmonary TB, 2 patients with known extrapulmonary TB, and 1 patient with previously identified latent TB at the time of appendicitis symptom onset.

Fig. 2 demonstrates the country of origin for patients. Eighteen cases were reported from India and East/Southeast Asia; 6 cases from the Middle East; 6 cases from Africa; 2 cases from South America; and 2 cases from Europe.

Diagnostic data is reported in Table 3. Leukocytosis was noted in 19 patients (56%). Diagnostic methodology was reported in 28 cases. Fourteen patients (41%) were diagnosed by ultrasound (US), 10 patients

Table 1
Baseline characteristics.

Variable	Total patients = 34 (% total)
Average age, years (SD)	25.5 (8.81)
Male sex	20 (59)
Prior diagnosis of tuberculosis	2 (6)

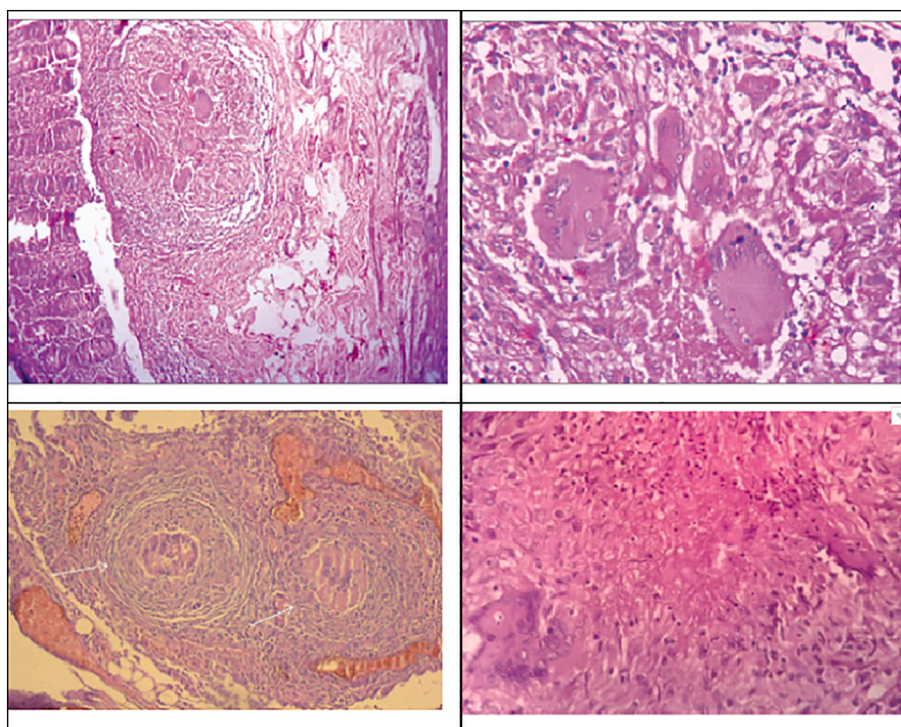


Fig. 1. a–d: Caseating granulomas with Langhans giant cells and epithelioid histiocytes.

Table 2
Presenting signs and symptoms.

Variable	Total patients = 34 (% total)
Acute onset or worsening of RLQ abdominal pain	28 (82)
Vague or generalized abdominal pain	12 (35)
Palpable abdominal mass	2 (6)
Fever	24 (71)
Nausea or vomiting	15 (44)
Diarrhea	4 (12)
Anorexia, weight loss, or loss of appetite	10 (29)
Cough	4 (12)
Hypotension	5 (15)
Median duration of symptoms, days (IQR)	10 (3.5–60)
Reported chronic symptoms	17 (50)

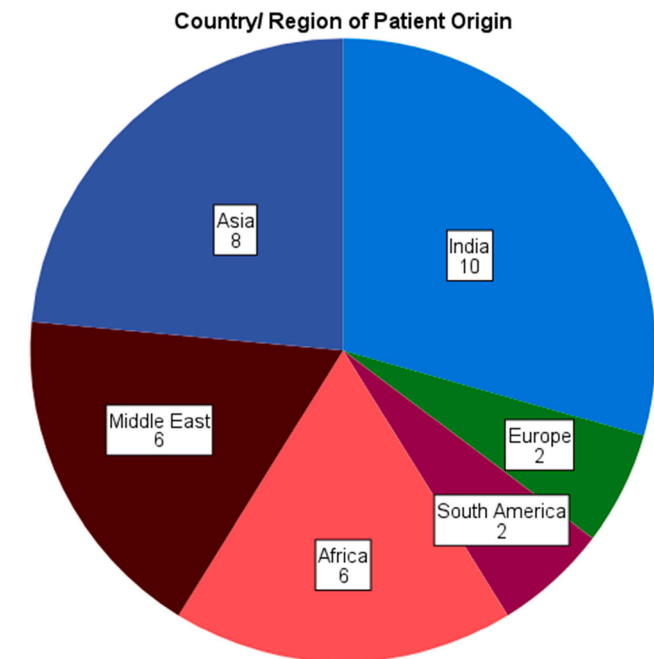


Fig. 2. Breakdown of patient country of origin.

Table 3
Diagnostic work up.

Variable	Total patients = 34 (% total)
Leukocytosis	19 (56)
Diagnostic modality	
Physical exam	4 (12)
Ultrasound	14 (41)
Computed Tomography	10 (29)
Enlarged or necrotic peri-appendiceal lymph nodes on imaging	5 (15)
Evidence of tuberculosis on chest CT or X-ray	7 (21)
Sputum AFB positive	6 (18)

(29%) by computed tomography of the abdomen/pelvis (CT), and 4 patients (12%) were diagnosed on physical exam alone. Chest X-ray (CXR) or chest CT results were reported in 24 patients. Seven of these patients (29%) had radiographic evidence of pulmonary tuberculosis.

Data regarding operative management and findings are reported in Table 4. Twenty six patients (76%) underwent an open surgery, including 13 who underwent exploratory laparotomy and 13 who underwent open appendectomy via right lower quadrant incision. Seven patients underwent laparoscopic appendectomy. Eight cases (24%) noted a perforated or ruptured appendix. Seven cases (21%) noted white

Table 4
Operative management and intraoperative findings.

Variable	Total patients = 34 (% total)
Laparoscopic appendectomy	7
Open appendectomy/RLQ incision	13
Exploratory laparotomy/midline incision	13
Ruptured, perforated, or necrotic appendix	8 (24)
Peritoneal studding with tubercles	7 (21)
Peritoneal fluid AFB positive	5 (15)

nodules/lesions on either the appendix, mesentery, or peritoneum. All 34 patients had final diagnosis determined on histology, with all samples displaying characteristic caseating granulomas, epithelioid histiocytes, and Langhans giant cells. AFB stain from either the appendix or peritoneal fluid sample was reported in 12 patients. AFB were present in the tissue or fluid samples of 5 patients (15%), and negative in 7 patients. Nearly all patients subsequently underwent pharmacotherapy on the HRZE regimen (isoniazid, rifampicin, pyrazinamide, and ethambutol), or a WHO-recommended alternative [18]. The average duration of treatment was 7.2 ± 1.7 months. Two patients completed an ATT course for less than 6 months and were reportedly well at their routine follow up exam. One patient completed a WHO-recommended alternative for multi-drug resistant TB.

5. Discussion

The pathophysiology of appendiceal tuberculosis is complex and relatively uncertain. Singh and colleagues proposed classifications and subgroupings regarding the etiology of tuberculous appendicitis: primary appendicitis due to appendiceal contact with infected intestinal contents, direct hematogenous spread from a distant source such as the lung; or secondary appendicitis due to local extension of ileocecal tuberculosis, retrograde lymphatic spread in the ileum/ascending colon, or appendiceal serositis/periappendicitis from peritoneal involvement [19]. It was noted in the pair of cases from Akbulut et al. that 2 patients who developed tuberculous appendicitis had lesions noted at the appendiceal orifice on colonoscopy performed 2 months prior to onset of appendicitis [17]. Logic would dictate that primary inoculation from swallowing of the expectorated phlegm of pulmonary TB should offer the most easily identifiable risk factor for developing tuberculous appendicitis [20]. However, from our review of published cases, only one patient presented with appendicitis in the setting of active pulmonary tuberculosis. Appendicitis was the initial presentation and primary mode for diagnosis of TB in the remaining patients.

Because of the lack of capability for pre-operative diagnosis, prompt identification is dependent upon a high index of suspicion, considering patient demographics, as well as history and presenting symptoms. Radiologic and laboratory results will support clinical suspicion.

In the US, patients who are born in a country with endemic TB (especially from Asia, the Middle East, or Africa), who present with vague chronic complaints prior to acute abdominal pain, or who complain of chronic abdominal pain represent the highest likelihood of tuberculous appendicitis. Necrotic lymph nodes represent the only potential differentiating finding on abdominal imaging.

The only reported cases of tuberculous appendicitis in North America over the past 10 years involved patients who had immigrated to the continent after childhood. According to the Centers for Disease Control (CDC), 70% of TB diagnoses in 2017 were made in foreign-born individuals [21]. In the clinical experience of the primary author, tuberculous appendicitis has been seen only once, and was diagnosed in a patient who had immigrated to the US from China for education. This data does not imply that only foreign-born patients will develop tuberculous appendicitis, but it does offer a data point from the patient's history that should raise clinical suspicion of the disease for surgeons in the US. For reference, the World Health Organization (WHO) lists 22

countries which see 80% of worldwide TB diagnoses [22].

A preoperative chest X-ray can be considered if the surgeon has a high index of suspicion for tuberculous appendicitis. Due to the often urgent nature of appendicitis, the young age of affected patients, and typical lack of notable medical history, a chest X-ray is frequently not performed. However, if there is a high index of suspicion for tuberculous etiology in a hemodynamically stable patient with appendicitis, a preoperative chest X-ray can be performed to support clinical judgement. Characteristic chest X-ray findings for tuberculosis include infiltrates, consolidations, cavitating nodules, with or without mediastinal/hilar lymphadenopathy [21].

Peritoneal implants were noted in a quarter of patients. This may be a useful finding intraoperatively. In older patients, peritoneal studding is more worrisome for carcinomatosis. However in patients with tuberculous appendicitis, who are noted to typically be younger, this could support a suspicion of TB as the causative organism for the patient's appendicitis.

Our review notes that AFB stain is positive in abdominal fluid in less than 30% of patients, making the culture of *M. tuberculosis* difficult. While these numbers are low, sending peritoneal fluid and appendiceal tissue for Ziehl-Neelsen (acid fast) stain will typically yield a result within 24 h of sample arrival to the laboratory. This may provide an earlier diagnosis of tuberculous appendicitis and an earlier indication or justification for placing the patient in isolation than would be afforded by pathology results. Culture of abdominal fluid will also take longer to yield results, but will only aid in making the final diagnosis and support histology findings.

At institutions where it is available, nucleic acid amplification (NAA) is a useful adjunct to the classic mode of histologic diagnosis. If peritoneal fluid is found during surgery, samples can be sent for amplification. NAA tests are highly sensitive and specific for TB, and a result can be obtained in a matter of hours. However as with any rare disease, their positive predictive value is usually quite low. The CDC and WHO both recommend NAA tests as adjunctive data points for early detection of a likely TB infection, when available. However, this testing alone is not considered diagnostic and a positive result must be later confirmed and diagnosed by culture. NAA was scarcely reported in the literature reviewed by this study, and so commentary on its usefulness in the diagnosis of tuberculous appendicitis has been omitted, but it is worth considering for future study as a modality for more prompt identification of tuberculous appendicitis (Fig. 3).

Initiation of ATT still requires tissue diagnosis at this time. While guidelines exist for treatment of latent disease [23], tuberculous appendicitis is an extrapulmonary manifestation of active disease, which is typically treated according to the WHO's guidelines of 6 months treatment duration (WHO tx). This strategy proved effective in curing all

cases of tuberculous appendicitis reported in this literature review. Two reported cases completed a course of treatment for less than 4 months, with successful eradication of symptoms and no evidence of tuberculosis at follow-up. However, this is not recommended as it carries the risk of sub-cidal treatment and the generation of multi-drug resistant tuberculosis (MDR-TB) [24].

The major limitation of this paper is the quality of data due to the nature of its collection. Presenting symptoms, diagnosis, and management were not standard between case reports. Because of this, the data collected was incomplete in several variables. However, due to the low incidence of tuberculous appendicitis, it is felt that more intense study will likely not be possible. Due to the low incidence of tuberculous appendicitis, a high powered study will also likely not be possible. Another factor not discussed earlier is the possibility of incorrect diagnosis by a pathologist. While tuberculosis has several characteristic histologic findings, it is possible to identify granulomas, both caseating and noncaseating, in a number of other conditions. These include *Yersinia enterocolitica* infection, parasitic infections, Crohn's disease, sarcoidosis, or foreign body reactions [12,25]. While these conditions will likely not be seen in combination with both epithelioid histiocytes and Langhans giant cells, it nonetheless bears consideration when assessing the patient [26].

While this paper attempted an exhaustive search of the literature over the past 10 years, it remains distinctly possible that some case reports remain omitted due to a lack of reporting in the included databases. While this review may be considered an extensive search of the available literature, it certainly may not be a complete one. It should be noted that all reports encountered in Pubmed and Google Scholar were encountered in the other databases that were searched. A search of the other databases did not yield any additional case reports outside of those already encountered in Pubmed and Google Scholar that fit the inclusion and exclusion criteria.

6. Conclusions

We do not yet possess the means to definitively identify appendiceal tuberculosis in patients pre-operatively. In lieu of a method of formal preoperative diagnosis, our aim is to provide a summary characterization of patients with tuberculous appendicitis so that higher risk patients may be identified. Nearly one third of tuberculous appendicitis patients will present with chronic "classic" symptoms of tuberculosis prior to the onset of abdominal symptoms. These patients often originate from countries with endemic tuberculosis. Even with cases seen in North America or Europe, patients will typically have immigrated from endemic regions. Tuberculous appendicitis is a disease primarily affecting young patients, especially males. Objective data offers suggestions of tuberculous appendicitis, but there does not appear to be a sensitive or specific enough laboratory or imaging finding to make a preoperative diagnosis. Radiologic evidence of tuberculous appendicitis does not appear to differ significantly from non-tuberculous appendicitis; the only notable difference being necrotic lymph nodes mentioned on CT scans in 5 cases. Less than a third of patients will have identifiable lesions on perioperative chest X-ray. Intraoperatively, approximately a quarter of patients will have tubercles or studding noted either on the appendix, mesentery, or peritoneum. Open surgery has largely been performed on these patients. At this point, tuberculous appendicitis can only be considered amongst a patient's differential diagnosis, taking into consideration multiple history, physical, and laboratory/radiologic data points. A high index of suspicion can be generated with these data points, but we do not yet possess the means to diagnose tuberculous appendicitis prior to histologic examination.

7. Declarations and statements

The Corresponding Author has the right to grant on behalf of all authors and does grant on behalf of all authors, an exclusive licence on a

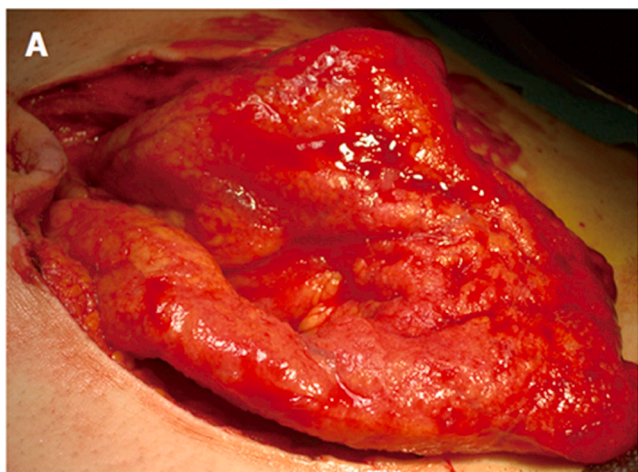


Fig. 3. Tubercles studded on visceral peritoneum [9].

worldwide basis to the to permit this article (if accepted) to be published in the Journal of Clinical Tuberculosis and Other Mycobacterial Diseases and sublicences such use and exploit all subsidiary rights, as set out in the licence.

Transparency declaration: The lead author affirms that the manuscript is an honest, accurate, and transparent account of the study being reported; no important aspects of the study have been omitted.

Ethics statement: this study did not require ethical approval as it pulled information and analyzed data from already published and available work.

Funding: this study did not receive any funding.

Author role details: Grant Hubbard: lead data collection and writer. Walter Chlysta: writer, editor, research mentor.

Patient and public involvement: neither the public nor any patients were involved in the writing of this manuscript.

Declaration of Competing Interest

The authors declare that they have no known competing financial interests or personal relationships that could have appeared to influence the work reported in this paper.

References

- Jensen PA, Lambert LA, Iademarco MF, Ridzon R. CDC. Guidelines for preventing the Transmission of Mycobacterium tuberculosis in Health-care settings. *MMWR Recomm Rep* 2005;54(RR-17):1–141. https://www.cdc.gov/mmwr/preview/mmwrhtml/rr5417a1.htm?s_cid=rr5417a1_e. Accessed January 28, 2020.
- Bercu TE, Rubin ZA, Agopian VG. Tuberculous appendicitis. *Am J Med* 2011;124(2):e9–10.
- Borrow ML, Friedman S. Tuberculous appendicitis. *Am J Surgery* 1956;91(3):389–93.
- Rasheed S, Zinicola R, Watson D, Bajwa A, McDonald PJ. Intra-abdominal and gastrointestinal tuberculosis. *Colorect Dis* 2007;9(9):773–83.
- World Health Organization. Global tuberculosis report: 2016. 2016;2–3. <https://apps.who.int/iris/bitstream/handle/10665/250441/9789241565394-eng.pdf?sequence=1>.
- Nathavitharana RR, Bond P, Dramowski A, Kotze K, Lederer P, Oxley I, Peters JA, Rossouw C, van der Westhuizen H-M, Willems B, Ting TX, von Delft A, von Delft D, Duarte R, Nardell E, Zumla A. Agents of change: the role of healthcare workers in the prevention of nosocomial and occupational tuberculosis. *La Presse Méd* 2017;46(2):e53–62.
- Pai M, Kalantri S, Aggarwal AN, Menzies D, Blumberg HM. Nosocomial tuberculosis in India. *Emerg Infect Dis* 2006;12(7):1311–8.
- Adada H, Valley MA, Nour SA, Mehta J, Byrd RP, Anderson JL, Roy T. Epidemiology of extra-pulmonary tuberculosis in the United States: high rates persist in the post-HIV era. *Int J Tuberc Lung Dis* 2014;18(12):1516–21.
- Barbagallo F, Latteri S, Sofia M, et al. Appendicular tuberculosis: the resurgence of an old disease with difficult diagnosis. *World J Gastroenterol* 2010;16(4):518–21.
- Elamurugan TP, Sivashanker M, Kumar SS, Muthukumarassamy R, Kate V. Primary tuberculous appendicitis presented with cecal perforation: a case report. *Asian Pac J Trop Med* 2012;5(10):834–6.
- Debi U, Ravisankar V, Prasad KK, Sinha SK, Sharma AK. Abdominal tuberculosis of the gastrointestinal tract: Revisited. *World J Gastroenterol* 2014;20(40):14831–40.
- Abdulgafar B. Granulomatous diseases and granulomas of the appendix. *Int J Surg Pathol* 2010;18(1):14–20.
- Singh A, Sahu MK, Panigrahi M, Behera MK, Uthansingh K, Kar C, Narayan J. Abdominal tuberculosis in Indians: Still very pertinent. *J Clin Tubercul Other Mycobact Dis* 2019;15:100097.
- Cheng W, Zhang S, Li Y, Wang J, Li J. Intestinal tuberculosis: clinico-pathological profile and the importance of a high degree of suspicion. *Trop Med Int Health* 2019;24(1):81–90.
- Vinay HG, Girish TU, Sharath Chandra BJ, Thrishuli PB. Primary tuberculosis of the appendix: a rare cause of a common disease. *J Surg Tech Case Report* 2013;5(1):32.
- Chong VH, Telisinghe PU, Yapp SKS, Chong CF. Tuberculous appendicitis: a review of clinical presentations and outcomes. *Singapore Med J* 2011;52(2):91–3.
- Akbulut S, Yagmur Y, Bakir S, Sogutcu N, Yilmaz D, Senol A, Bahadir MV. Appendicular tuberculosis: review of 155 published cases and a report of two cases. *Eur J Trauma Emerg Surg* 2010;36(6):579–85.
- World Health Organization. Treatment of tuberculosis: Guidelines for treatment of drug-susceptible tuberculosis and patient care. <https://apps.who.int/iris/bitstream/handle/10665/255052/9789241550000-eng.pdf?sequence=1>. Accessed January 28, 2020.
- Singh MK, Arunabh KVK. Tuberculosis of the appendix – a report of 17 cases and a suggested etiopathological classification. *Postgrad Med J* 1987;63(744):855–7.
- Sheer TA, Coyle WJ. Gastrointestinal tuberculosis. *Curr Gastroenterol Rep* 2003;5(4):273–8.
- Centers for Disease Control and Prevention. Guidelines for screening for Tuberculosis infection and disease during the domestic medical examination for newly arrived refugees. <https://www.cdc.gov/immigrantrefugeehealth/pdf/TB-domestic-guidelines-h.pdf>. Accessed January 2, 2020.
- World Health Organization. Global tuberculosis report 2019. https://www.who.int/tb/publications/global_report/en/. Accessed January 28, 2020.
- World Health Organization. Latent tuberculosis infection: Updated and consolidated guidelines for programmatic management. 2018. <https://apps.who.int/iris/bitstream/handle/10665/260233/9789241550239-eng.pdf?sequence=1>. Accessed January 28, 2020.
- Rumende CM. Risk factors for multi-drug resistant tuberculosis. *Acta Med Indones* 2018;50(1):1–2.
- Harris S, Ansari M, Gupta A, Afroz N. Isolated appendicular tuberculosis: a rare cause of acute appendicitis. *J Exp Integr Med* 2015;5(2):114.
- Akbulut S, Tas M, Sogutcu N, Arikanoğlu Z, Basbu M, Ulku A, et al. Unusual histopathological findings in appendectomy specimens: a retrospective analysis and literature review. *World J Gastroenterology* 2011;17(15):1961–70.
- Ardalan MR, Shoja MM, Ghabili K. Concomitant pulmonary tuberculosis tuberculous appendicitis in a recipient of a renal transplant: a case report. *J Med Case Rep* 2011;5:191.
- Bhushan VST, Mulla MA, Kumar V. Ruptured appendix in tuberculous abdome. *RGUHS Med Sci* 2015;5(1).
- Chis BA, Dudric V, Fodor D. Tuberculous appendicitis: a case report. *Med Ultrason* 2017;19(3):333–5.
- Constantinescu C, Vayalunkal J, Fisher D. An unusual case of appendicitis. *Can Med Assoc J* 2014;186(16):1241–3.
- Dalugama C, Jayasinghe A, Abeygunawardena S, Pathirage M, Jayalath T, Ralapanawa U, Jayasundara SS, Wijetunga S. Young male presenting with an acute diarrheal illness with unexplained transudative ascites: an atypical presentation of appendicular tuberculosis. *Case Rep Inf Dis* 2020;2020:1–5.
- Gonie A, Bekele K. Perforated tuberculous appendicitis: a rare case report. *Internat Med Case Rep J* 2018;11:129–31.
- Ito N, Kawamoto S, Inada K, et al. Primary tuberculosis of the appendix in a young male: report of a case. *Surg Today* 2010;40(7):668–71.
- Krishna M, Dayal S, Kumar A. Primary tuberculosis of the appendix: a common disease with rare location – a rare case report from rural India. *North Clin Istanbul* 2020;7(3):298–301.
- Maharjan S. An uncommon case of chronic tubercular appendicitis. *Case Rep Pathol* 2015;2015:1–4.
- Moniri A, Marjani M, Tabarsi P, Baghaei P, Dorudinia A, Masjedi MR. Multidrug-resistant tubercular appendicitis: report of a case. *Int J Mycobacteriol* 2013;2(4):227–9.
- Mountassir M, Ennafe I, Kechna H, Samir B, ElKandry S. An isolated case of tuberculosis of the appendix. *Pan Afr Med J* 2011;9(16).
- Nam S-H, Kim JS, Kim KH, Park SJ. Primary tuberculosis appendicitis with mesenteric mass. *J Korean Surg Soc* 2012;82(4):266.
- Okoro KU, De La Espriella MG, Grider DJ, Baffoe-Bonnie AW. Tuberculous appendicitis presenting as acute appendicitis and perirectal abscess. *Case Rep Med* 2018:1–6.
- Pal S, Bose K, Chowdhury M, Sikder M. Tuberculous appendicitis: a rare case report. *CHRISMED J Health Res* 2016;3(2):144.
- Rabbani K, Narjis Y, Difaa A, Louzi A, Benelkhaiat R, Finech B. Tuberculous appendicitis. *Saudi J Gastroenterol* 2011;17(4):287.
- Rodriguez N, Gomez N. Apendicitis aguda perforada secundaria, a una tuberculosis como causa de sepsis posparto. *Rev Chilena Infectol* 2020;37(2):186–9.
- Tesfamariam Sengal A, Abdalla Mohamedani A, Hussein HH, Kamal A. The role of PCR in diagnosis of a rare appendicular tuberculosis and mini literature review. *Case Rep Gastrointestinal Med* 2016;2016:1–3.
- Tauro LF, Aithala PS, George SRC, Hanumanthappa, Martis J. Primary tuberculosis of the appendix. *Oman Med J* 2010;25(3).
- Youssef A, Neji K, Amara FB, Reziga H. Primitive caeco-appendicular tuberculosis revealed by perforation at 33 weeks of pregnancy. *Tunis Med* 2014;92(4):290–1.
- Ambekar S, Bhatia M. Appendicular tuberculosis: a less encountered clinical entity. *BMJ Case Rep* 2021;14(2):e237718.